

## DENTAL DISEASE

### *How common is dental disease in cats?*

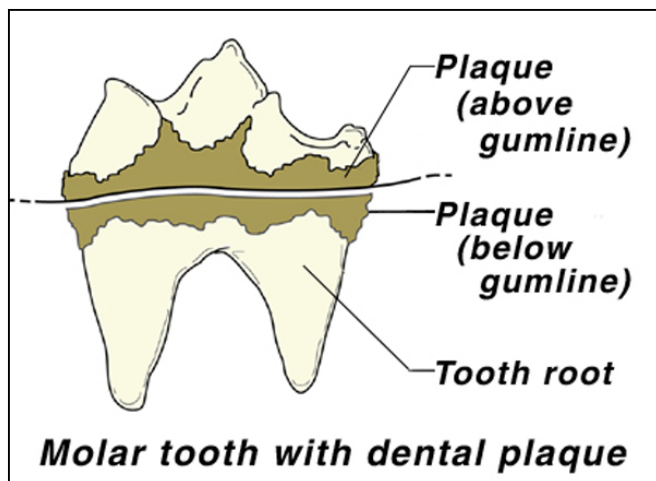
Dental disease is the most frequent condition seen by veterinarians. Approximately two-thirds (68%) of cats over three years of age have some degree of dental disease. The most common problems are due to periodontal disease, gingivitis and cervical neck lesions (also called resorptive lesions or odontoclastic lesions).

### *What signs am I likely to see?*

There are a number of signs that should alert you to dental disease or other mouth problems presenting your cat. Your cat may show a decreased interest in food, or approach the food bowl and then show a reluctance to eat. It may chew with obvious caution and discomfort, drop food from the mouth, or may swallow with difficulty. Dribbling may be seen, possibly with blood, and there may be a marked unpleasant odor to the breath. In some cases the cat may be seen pawing at their mouth or head shaking. A reluctance to eat may lead to weight loss, which can become quite marked. Many cats will refuse dry food and demonstrate a preference for moist or canned foods. Dental disease and oral pain may account for the “finicky appetites” that many cats display.

### *What causes dental disease?*

The most common cause of dental disease in cats is due to tartar and calculus accumulation. As in humans, cats accumulate bacterial plaque on the surface of their teeth. If the plaque is not removed quickly, it becomes mineralized to form tartar and calculus. The bacterial products and decaying food stuck to tartar are one potential cause of bad breath.



Tartar is easily identified by its tan or brown color - it normally starts at the gum edge, especially on the back teeth (premolars & molars). In severe cases it may cover the entire tooth.

The accumulation of tartar and bacteria on the teeth surfaces lead to infection and **gingivitis** (inflammation of the gums). If the disease is caught at an early stage and a thorough veterinary dental scaling and polishing

performed, most of the teeth and gums will have a full recovery. However, if gingivitis is allowed to persist untreated, then irreversible **periodontal disease** will occur. During this process the bone and ligaments that support the tooth are destroyed leading to excessive tooth mobility and eventual tooth loss. Infection around the socket causes the formation of pus and a foul odor and may spread deep into the tooth socket creating an abscess, or even more severe problems.

Once periodontal disease starts, the degenerative changes cannot be reversed. These changes make it easier for more plaque and tartar to collect, resulting in further disease.

### *Is gingivitis always associated with dental disease?*

*Thank you for choosing Pearland Animal Hospital.  
Please call (281) 485-2496 if you have any questions or concerns.*



A slight degree of redness seen as a thin line just below the edge of the gum may be considered normal in some kittens and adult cats with no evidence of dental disease.

Some cats develop severe gingivitis with minimal signs of accompanying dental disease. The affected areas may extend beyond the gums to other areas of the mouth, such as the throat or tongue. The cause of this condition is not fully understood but it is likely to be multi-factorial and may differ between individual cases. This condition is often very difficult to control and may require repeated or constant treatment, and its accurate diagnosis can involve extensive investigative procedures.

#### ***What are cervical neck lesions?***

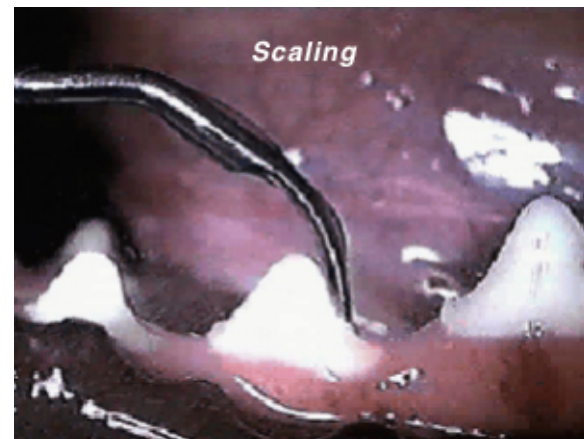
Cervical neck lesions result from a progressive destruction of the enamel resulting in slowly deepening “holes” in affected teeth. Once the sensitive parts of the tooth are exposed, these lesions are intensely painful, and the only available treatment is to extract the tooth. The cause of this disease is unknown; however, poor oral hygiene is suspected to play a role in the disease-process.

#### ***What should I do if my cat has signs of dental problems?***

If you see that your cat has evidence of tartar accumulation, gingivitis or is exhibiting any signs of mouth pain or discomfort, you should take it to your veterinarian for an examination. You will be advised of the most appropriate course of treatment, which may involve having the cat’s teeth examined and cleaned under short-acting general anesthesia.

The rate of tartar accumulation is very variable between individual cats, and in some cases this may necessitate professional cleaning on a regular basis (every 6-12 months).

Do not try to remove tartar from the teeth yourself using any form of metallic instrument. Aside from potentially harming your cat’s mouth (or the cat harming you), you are likely to damage the tooth surface by creating microscopic scratches, which will encourage more rapid plaque formation and cause further disease.



#### ***What can I do to help prevent dental disease in my cat?***

The prime aim to help prevent dental disease is to keep the mouth as hygienic as possible and to reduce the rate at which tartar builds up on the teeth.

Recent advances in nutrition have resulted in diets that reduce tartar accumulation. Your veterinarian can give you specific dietary recommendations that will benefit your pet’s dental health.

The most effective way of reducing plaque and tartar is to brush the teeth. A number of toothpastes and brushes are available from your veterinarian which are specially designed for a cat’s mouth. With gentleness, patience and perseverance it is possible to regularly clean some cats’ teeth in this way. In addition, or as an alternative to brushing if this cannot be achieved, a range of antibacterial mouthwashes and gels can be applied to the teeth and mouth to reduce the number of bacteria present. Please ask your veterinarian for further details regarding available dental products for your cat.

**Never use human toothpaste on cats, as these are not designed to be regularly swallowed and could cause problems.**

*Thank you for choosing Pearland Animal Hospital.  
Please call (281) 485-2496 if you have any questions or concerns.*